



ADVANCING
PERFORMANCE
TOGETHER

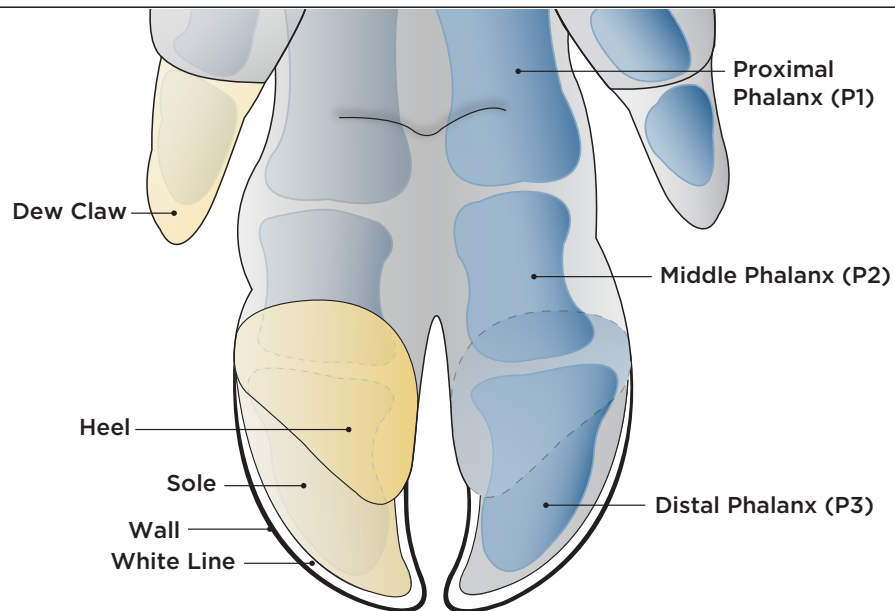
LESION SCORING GUIDE

FOR SWINE

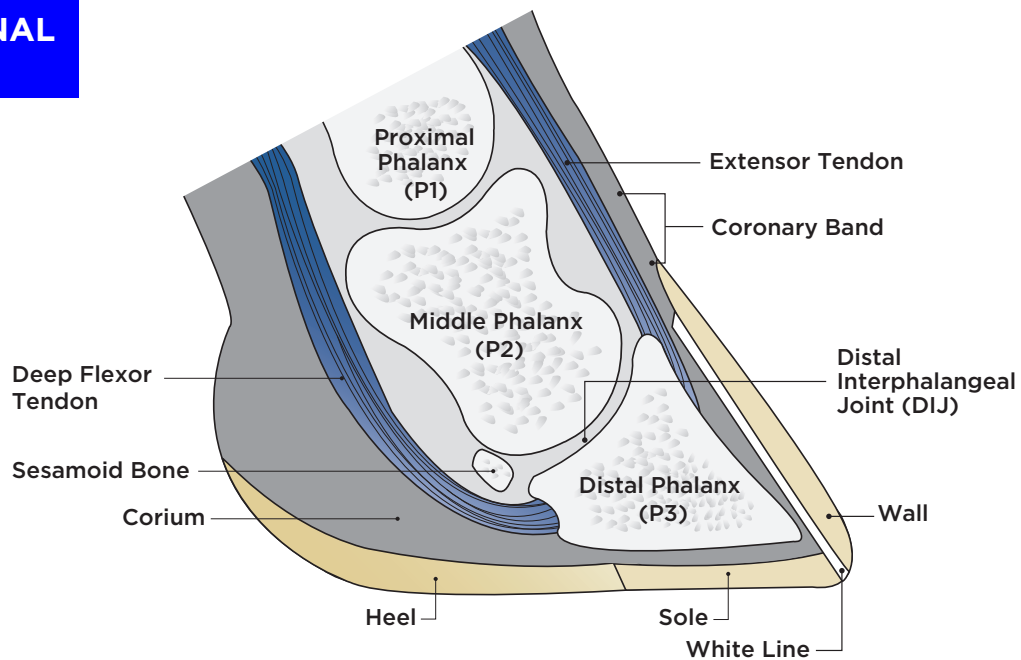
LESION DESCRIPTION	TOES (T)	DEW CLAWS (DC)	HEEL OVERGROWTH AND EROSION (HOE)	HEEL-SOLE CRACK (HSC)	WHITE LINE (WL)	CRACKED WALL HORIZONTAL (CWH)	CRACKED WALL VERTICAL (CWV)
1 MILD	 <p>One or more toes slightly longer than normal</p>	 <p>Slightly longer than normal</p>	 <p>Slight overgrowth and/or erosion in soft heel tissue</p>	 <p>Slight separation at the juncture</p>	 <p>Shallow and/or short separation along white line</p>	 <p>Hemorrhage evident, short/shallow horizontal crack in toe wall</p>	 <p>Short/shallow vertical crack in wall</p>
2 MODERATE	 <p>One or more toes significantly longer than normal</p>	 <p>Claws extend to floor surface when the pig is standing</p>	 <p>Numerous cracks with obvious overgrowth and erosion</p>	 <p>Long separation at the juncture</p>	 <p>Long separation along white line</p>	 <p>Long but shallow horizontal crack in toe wall</p>	 <p>Long but shallow vertical crack in wall</p>
3 SEVERE	 <p>Long toes that affect gait when walking</p>	 <p>Claw is torn and/or partially or completely missing</p>	 <p>Large amount of erosion and overgrowth with cracks throughout</p>	 <p>Long and deep separation at the juncture</p>	 <p>Long and deep separation along white line</p>	 <p>Multiple or deep horizontal crack(s) in toe wall</p>	 <p>Multiple or deep vertical crack(s) in wall</p>

Anatomy of a Pig's foot

REAR VIEW



LONGITUDINAL SECTION



For more information: contact your Zinpro® representative or visit zinpro.com/swine

Produced by the Zinpro FeetFirst Team
Dr. J. Deen, Dr. M. Schuttert, Dr. S. van Amstel,
Dr. P. Ossent, Dr. R. van Barneveld and
Zinpro Corporation